



## Dermatology Reports

<https://www.pagepress.org/journals/index.php/dr/index>

eISSN 2036-7406



**SIDCO**

Società Italiana di Dermatologia  
Chirurgica, Oncologica, Correttiva ed Estetica

**Publisher's Disclaimer.** E-publishing ahead of print is increasingly important for the rapid dissemination of science. **Dermatology Reports** is, therefore, E-publishing PDF files of an early version of manuscripts that undergone a regular peer review and have been accepted for publication, but have not been through the copyediting, typesetting, pagination and proofreading processes, which may lead to differences between this version and the final one. The final version of the manuscript will then appear on a regular issue of the journal. E-publishing of this PDF file has been approved by the authors.

*Please cite this article as: Nguyen TTT, Hoang ANN, Luu TNA, et al. Diverse clinical manifestations of acquired vulvar lymphangioma: a report of five cases in Vietnamese women. Dermatol Rep 2023 [Epub Ahead of Print] doi: 10.4081/dr.2024.9888*



© the Author(s), 2024  
Licensee PAGEPress, Italy

Submitted: 07/11/2023 – Accepted 12/11/2023

Note: The publisher is not responsible for the content or functionality of any supporting information supplied by the authors. Any queries should be directed to the corresponding author for the article.

All claims expressed in this article are solely those of the authors and do not necessarily represent those of their affiliated organizations, or those of the publisher, the editors and the reviewers. Any product that may be evaluated in this article or claim that may be made by its manufacturer is not guaranteed or endorsed by the publisher.

## **Diverse clinical manifestations of acquired vulvar lymphangioma: a report of five cases in Vietnamese women**

Tho Thi Thanh Nguyen,<sup>1</sup> Anh Nguyen Ngoc Hoang,<sup>1</sup> Thu Nguyen Anh Luu,<sup>1</sup> Thuy Thi Phan Nguyen,<sup>1</sup> Em Van Loi Doan,<sup>1</sup> Tu Nguyen Anh Tran,<sup>1</sup> Hao Trong Nguyen<sup>1,2</sup>

<sup>1</sup>Ho Chi Minh City Hospital of Dermato-Venereology, Ho Chi Minh City; <sup>2</sup>Pham Ngoc Thach University of Medicine, Ho Chi Minh City, Vietnam

**Correspondence:** Hao Trong Nguyen, Ho Chi Minh City Hospital of Dermato-Venereology, 2 Nguyen Thong, Ward Vo Thi Sau, District 3, Ho Chi Minh City, Vietnam.

Tel.: +84.903639234.

Fax: +84.2839304810.

E-mail: bshao312@yahoo.com

**Key words:** acquired vulvar lymphangioma; diverse manifestations.

**Acknowledgments:** The authors thank the STIs Clinic of Ho Chi Minh City Hospital of Dermato-Venereology for collecting the data.

**Contributions:** TTTN, ANNH, TNAL, TTPN, EVLD, acquisition of data; TTTN, ANNH, TNAL, TTPN, EVLD, TNAT, ATN, drafting the manuscript; ATN, critical revision for important intellectual content. All the authors approved the final version to be published.

**Conflict of interest:** the authors declare no potential conflict of interest.

**Funding:** none.

**Ethics approval and consent to participate:** this report received approval from the Research Ethics Committee of Ho Chi Minh City Hospital of Dermato-Venereology. The participants were clearly explained the study's objectives and protocols and written informed consent was obtained prior to study enrollment.

**Availability of data and material:** all data used to support the findings of this study are included within the article. Further enquiries can be directed to the corresponding author.

## **Abstract**

Acquired vulvar lymphangioma (AVL) is a rare but important condition that requires prompt diagnosis and appropriate management to alleviate symptoms and prevent complications. AVL can erupt locally as isolated or clustered lesions which range from translucent, fluid-filled vesicles to smooth, flesh-colored papules or nodules that exude serous or crystalline liquid spontaneously or after trauma. Clinically, it can also be asymptomatic. However, symptoms are commonly accompanied by vulvar itching, burning, soreness, or unpleasant discharge. Here, we report a case series of five Vietnamese patients with AVL with diverse clinical features.

## **Introduction**

Vulvar lymphangiomas are relatively rare benign malformations composed of dilated lymphatic vessels.<sup>1</sup> Only a few cases have been described in the literature. We report a case series of five adult female patients who presented with fluid-filled vulvar lesions (Figures 1, 2). Histopathological examination confirmed the diagnosis of (AVL).

## **Case report**

Table 1 summarizes the clinical characteristics of the patients. Their ages ranged from 47 to 78 years (mean age: 61 years). Two patients had a history of cancer treatment, one with lymphadenectomy, and the other with radiotherapy. All biopsy specimens showed identical histopathological findings (Figure 3). Blood vessels and lymphatic vessels were concentrated in the superficial dermis, interspersed with chronic inflammatory cells and fibrous tissue (Figure 3A). Thin-walled lymphatic cavities were dissected through collagen bundles in the dermis, with endothelial cells containing eosinophils, lymphocytes, and red blood cells (Figure 3B). No inflammation was observed in the dermis. No morphological characteristics suggestive of human papillomavirus (HPV) infection or dysplasia were observed.

## **Discussion and Conclusions**

AVL is a rare but important condition that requires prompt diagnosis and appropriate management to alleviate symptoms and prevent complications. AVL can erupt locally as isolated or clustered lesions. Lesions can range from translucent, fluid-filled vesicles to smooth, flesh-colored papules or nodules that exude serous or crystalline liquid spontaneously or after trauma. Clinically, it can also be asymptomatic. However, symptoms are commonly accompanied by vulvar itching, burning, soreness, or unpleasant discharge.<sup>1-3</sup> In addition, Gupta et al. reported that AVL can be an adverse outcome of hidradenitis suppurativa (HS).<sup>4</sup> This finding highlights the

importance of identifying comorbidities in patients with HS-related symptoms. Additionally, the emotional discomfort caused by this condition cannot be ignored; it can lead to aesthetic and psychosexual disorders in women who experience it.

Given its rarity, AVL diagnosis can be challenging. However, early identification plays a crucial role in the optimal management of this condition. Multidisciplinary management involving gynaecologists, dermatologists, radiologists, and pathologists is necessary due to the complex nature of the condition.

This entity can be confused with conditions such as genital and plane warts. However, there are key distinctions between these conditions that can help distinguish them. Genital warts are small, flesh-colored, vascularized papules in the genital area that are caused by the HPV. The lesions are usually painless and do not secrete fluid, but they can cause itching and bleeding during intercourse. In contrast, plane warts, which are also caused by viral infection, typically appear as small, flat, flesh-colored, or pink bumps on the skin surface. They can occur anywhere on the body, including the vulva, and are usually painless.

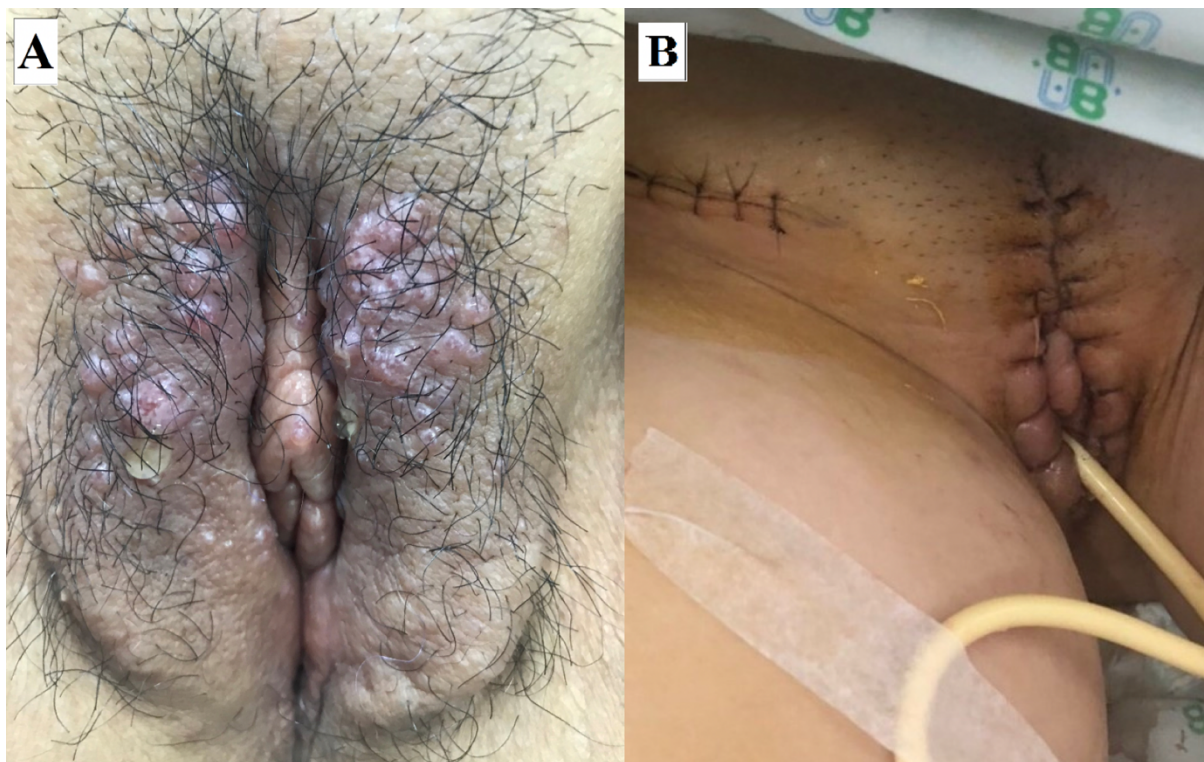
There is currently no established treatment protocol for AVL. Treatment options range from observational to invasive procedures, such as electrocoagulation, CO<sub>2</sub> laser therapy, sclerotherapy, and surgical excision, depending on the patient's condition. Surgical intervention is an effective treatment option in most cases of AVL. However, several factors must be considered during surgical planning, including lesion size, extent, and location, as well as careful consideration given to preserving functional anatomy while achieving adequate removal margins.

AVL can also have a significant psychological impact on women. It can affect their self-esteem, body image, and sexual function. Women with vulvar lymphangioma may also experience anxiety, depression, and other emotional difficulties coping with their condition and its impact on their lives. Families of women with AVL may also be affected as they provide emotional support and assist with care tasks. They may also experience stress and anxiety when dealing with the challenges of living with their family members. It is important that women with AVL and their families receive appropriate medical and psychological support to manage the physical and emotional impact of their condition and maintain their quality of life.

## References

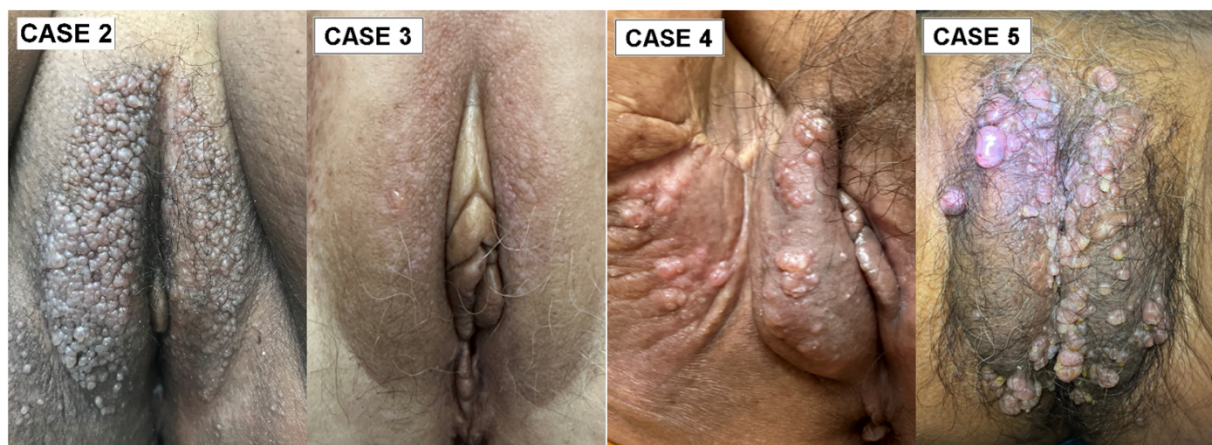
1. Griffiths CEM, Barker J, Bleiker TO, et al. Rook's textbook of dermatology, 4, Volume set 2016. Wiley: 105.34 –42

2. Mahajan RS, Marfatia YS, Shah AR, Ninama KR. Lymphangioma circumscriptum of the vulva- A case series. J Clin Diagn Res. 2021;15:WR01–WR4, [10.7860/JCDR/2021/47435.14553](https://doi.org/10.7860/JCDR/2021/47435.14553).
3. Marchitelli CE, Sluga MC, Domenech MM, et al. Report of 4 cases of vulvar lymphangioma: An update. Obstet Gynecol Int J. 2018;9:129–32, [10.15406/ogij.2018.09.00320](https://doi.org/10.15406/ogij.2018.09.00320).
4. Joseph P, Gupta N, Behl L, Mehak US. Acquired lymphangioma circumscriptum of the vulva in a middle aged woman with chronic hidradenitis suppurativa – A case report. IP J Diagn Pathol Oncol. 2023;8:46–9. doi, [10.18231/j.jdpo.2023.009](https://doi.org/10.18231/j.jdpo.2023.009).

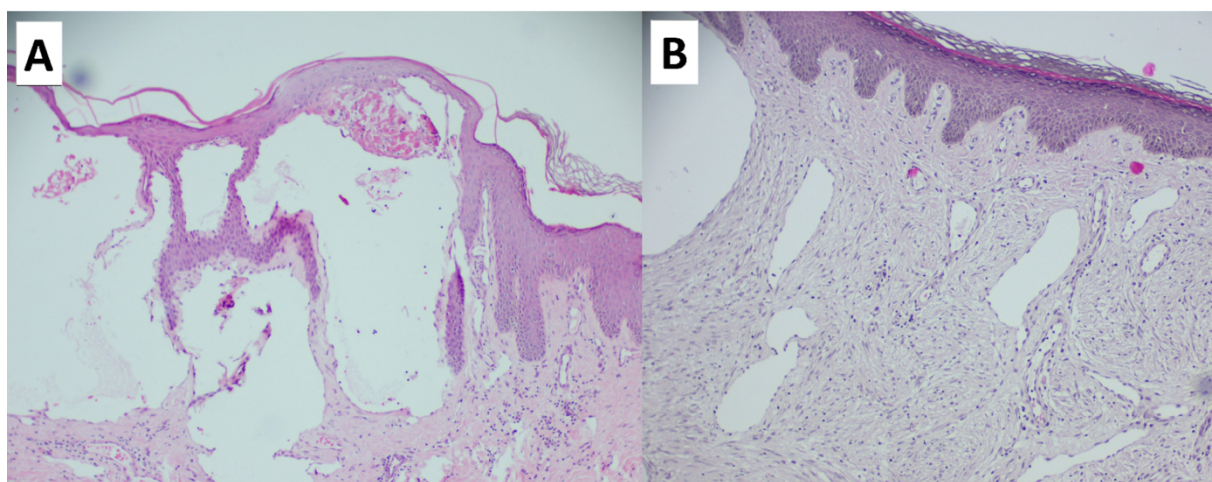


**Figure 1. Case 1. (A) before treatment, clear fluid-filled vesicles on the vulva, (B) after treatment.**





**Figure 2. Case 2: Clusters of vesicles resembling frogspawn. Case 3: Plane wart-like papules and vesicles. Case 4: Papules and fluid-filled vesicles. Case 5: Papules and pus-filled vesicles.**



**Figure 3. (A) Blood vessels and lymphatic vessels of various sizes, concentrated in the superficial dermis, alternating with chronic inflammatory cells, accompanied by fibrous tissue proliferation. (B) Thin-walled lymphatic vessels dissect through the dermis collagen bundles, with a layer of endothelial cells containing eosinophils mixed with lymphocytes and red blood cells.**

**Table 1. Clinical characteristics.**

Case	Age at	Predisposing conditions	Clinical presentation	Treatment	Follow-up (months)
------	--------	-------------------------	-----------------------	-----------	--------------------

	presentation (years)				
1	57	None	Clear fluid-filled vesicles	Bilateral superficial vulvectomy	6, no recurrence.
2	59	Cervical carcinoma, Cervicectomy	Genital warts like, greyish-pink papules resembling frogspawn.	Observation	Until present
3	65	None	Plane warts like papules and vesicles	Observation	Until present
4	47	Intra-articular synovial sarcoma in the hip joint, 25-ray radiotherapy	Painful, discomfort, itchy papules and fluid-filled vesicles	Observation	Until present
5	78	Cervical carcinoma, 25-ray radiotherapy	Painful, itchy papules and pus-filled vesicles	Observation	Until present