



Dermatology Reports

<https://www.pagepress.org/journals/index.php/dr/index>

eISSN 2036-7406



SIDCO

Società Italiana di Dermatologia
Chirurgica, Oncologica, Correttiva ed Estetica

Publisher's Disclaimer. E-publishing ahead of print is increasingly important for the rapid dissemination of science. **Dermatology Reports** is, therefore, E-publishing PDF files of an early version of manuscripts that undergone a regular peer review and have been accepted for publication, but have not been through the copyediting, typesetting, pagination and proofreading processes, which may lead to differences between this version and the final one. The final version of the manuscript will then appear on a regular issue of the journal. E-publishing of this PDF file has been approved by the authors.

Please cite this article as: De Piano E, Rubegni P, Cioppa V. A spear flap surgical revision. Dermatol Rep 2023 [Epub Ahead of Print] doi: 10.4081/dr.2024.9891



© the Author(s), 2024
Licensee PAGEPress, Italy

Submitted: 14/11/2023 – Accepted 12/01/2024

Note: The publisher is not responsible for the content or functionality of any supporting information supplied by the authors. Any queries should be directed to the corresponding author for the article.

All claims expressed in this article are solely those of the authors and do not necessarily represent those of their affiliated organizations, or those of the publisher, the editors and the reviewers. Any product that may be evaluated in this article or claim that may be made by its manufacturer is not guaranteed or endorsed by the publisher.

A spear flap surgical revision

Ernesto De Piano, Pietro Rubegni, Vittoria Cioppa

¹Unit of Dermatology, Department of Medical, Surgical and Neurological Sciences, University of Siena, Italy

Correspondence: Vittoria Cioppa, Viale Bracci 14, 53100, Siena, Italy.

Tel.: +39.3472827325.

E-mail: v.cioppa@student.unisi.it

Key words: spear flap; Mohs surgery; nasal ala.

Contributions: EDP was the Mohs surgeon. All the authors contributed equally to the manuscript.

Conflict of interest: the authors declare no potential conflict of interest.

Funding: none.

Availability of data and material: the data that support the findings of this paper are available from the corresponding author upon reasonable request.

Consent for publication: the patient gave his consent to use his personal data for the publication of this article and any accompanying images.

The case

A 55-year-old male presented with a recurrent infiltrative basal cell carcinoma of the right nasal ala. (Fig. 1A) Previous incomplete excision was repaired with second intention healing resulting in a contracted ala with columellar deviation and nostril asymmetry. (Fig. 1B) Complete tumor excision was achieved after three Mohs surgery stages, resulting in a full thickness defect involving the entire nasal ala and partially the sidewall. (Fig. 2A)

Our choice

A Spear flap was performed. After local anesthesia, the flap was incised starting from the lateral edge of the defect along and laterally to the nasolabial fold. (Fig. 2B) It was elevated including subcutaneous tissue, turned over and thinned. (Fig. 3A) The proximal part was sutured to the mucosal aspect of the defect. The cheek wound margin was undermined and advanced towards the nose in order to both close the secondary defect and reduce the primary. (Fig. 3B) The distal part of the flap was folded on the proximal and sutured. A triangular skin excess was removed from the sidewall. In order to prevent an unaesthetic lateral displacement of the nasal ala, the lateral aspect of the folded flap was rotated both medially and inferiorly.¹ (Fig. 4, yellow circle) After two months, despite this precaution, an unnatural lateral alar base insertion occurred. In addition, a vertical discrepancy was observed with a cephalic alar malposition. (Fig. 5) A surgical revision through an alar rotation flap was designed. A full thickness skin incision was performed in the alar crease extending to the alar base. After flap undermining, the nasal ala was rotated caudally. (Fig. 6A) This solution is similar to the Seesaw technique, but in our case no incisions in the alar-tip junction were made.² Finally, a Z-plasty allowed the alar base to move medially. (Fig. 6B)

The outcome

Sutures were removed after 7 days. (Fig. 7) Corrections were maintained after two years of follow-up. Columella deviation was reduced compared to before surgery. (Fig. 8)

Comment

The turnover nasolabial flap was first described by Spear *et al.* in 1987 as a single stage procedure for reconstructing large full thickness defects of the nasal ala involving the alar rim.³ This rapid solution often requires some postoperative revisions.

In order to achieve satisfactory results, surgeons must keep in mind the potential pitfalls.¹ Besides the lateral displacement, the risk of a vertical malposition of the nasal ala should be considered, especially when the defect involves the sidewall. In these cases, the cheek can be advanced to the nose in order

to completely close the sidewall defect before Spear flap folding.⁴ When vertical discrepancy still occurs, Seesaw technique represents an effective surgical revision.

References

1. Cook JL. Reconstruction of a full-thickness alar wound with a single operative procedure. *Dermatologic surgery: official publication for American Society for Dermatologic Surgery* [et al] 2003; 29(9): 956-62.
2. Hyun SM, Medikeri GS, Jung DH. The Seesaw Technique for Correction of Vertical Alar Discrepancy. *Plastic and reconstructive surgery* 2015; 136(3): 488-91.
3. Spear SL, Kroll SS, Romm S. A new twist to the nasolabial flap for reconstruction of lateral alar defects. *Plastic and reconstructive surgery* 1987; 79(6): 915-20.
4. Goldman GD. One-stage reconstruction following complete alar loss. *Dermatologic surgery : official publication for American Society for Dermatologic Surgery* [et al] 2006; 32(3): 418-22.

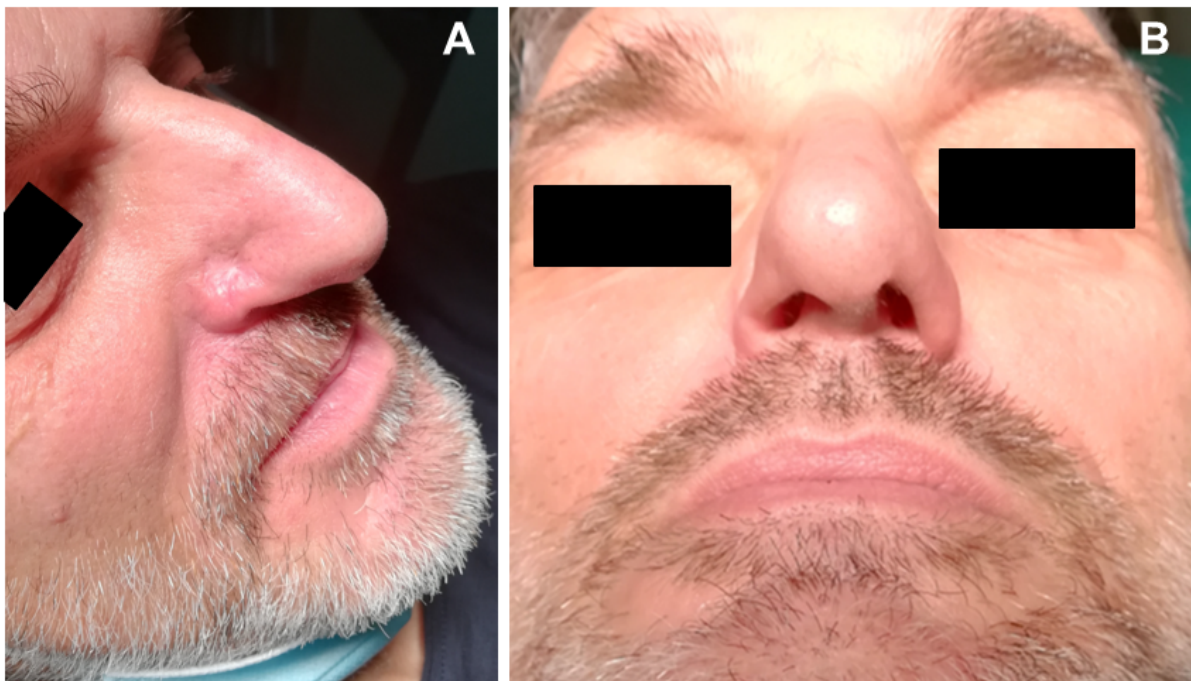

Figure 1. Basal cell carcinoma on the right nasal ala.

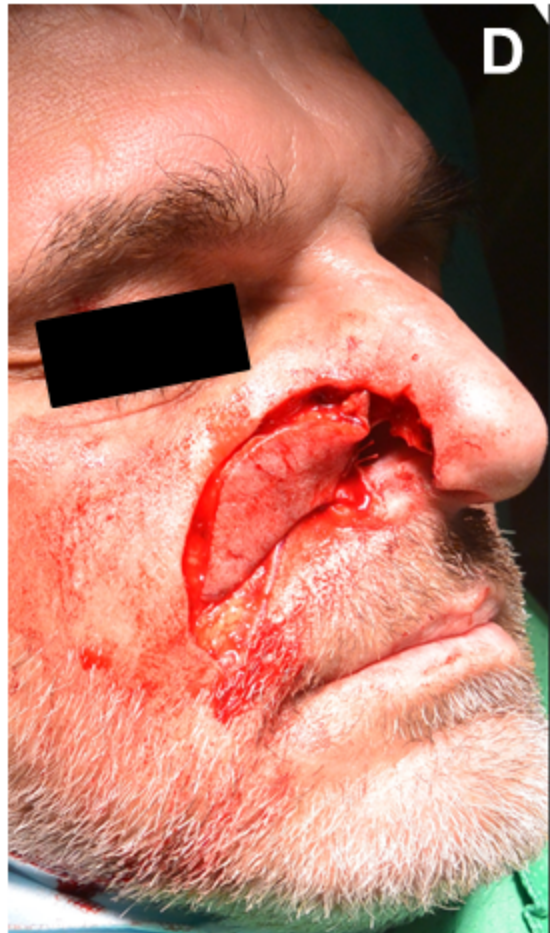
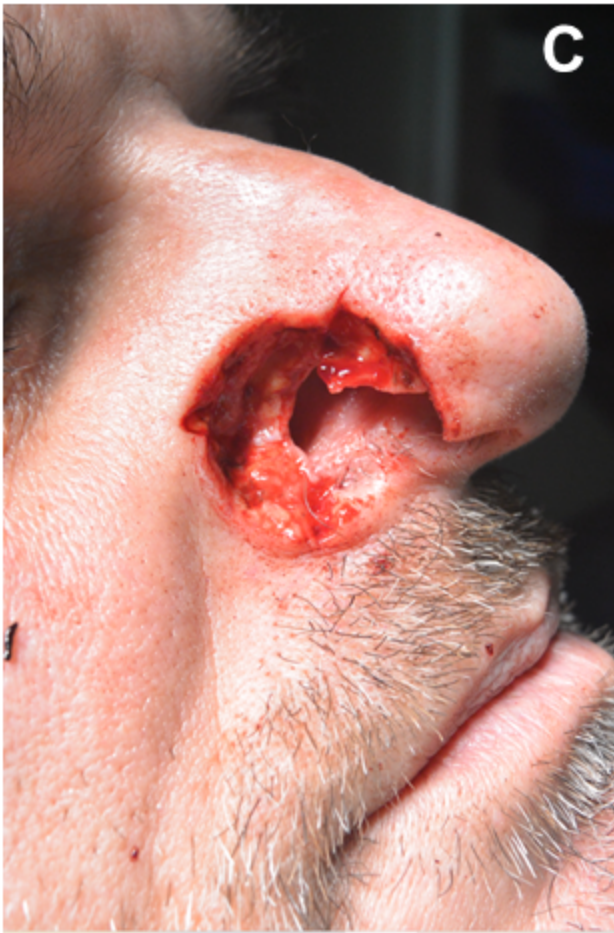
Figure 2. A) Full thickness defect involving the entire nasal ala; B) Spear flap.

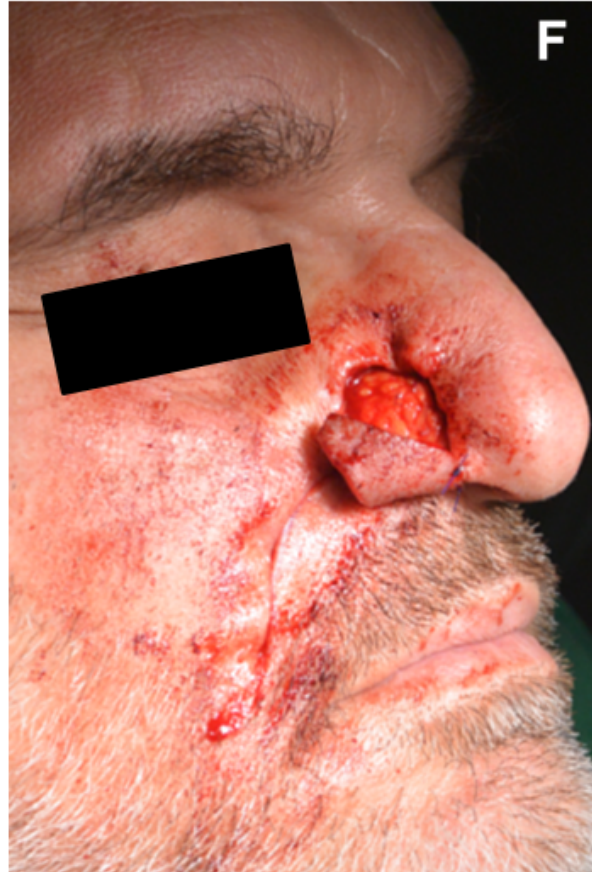
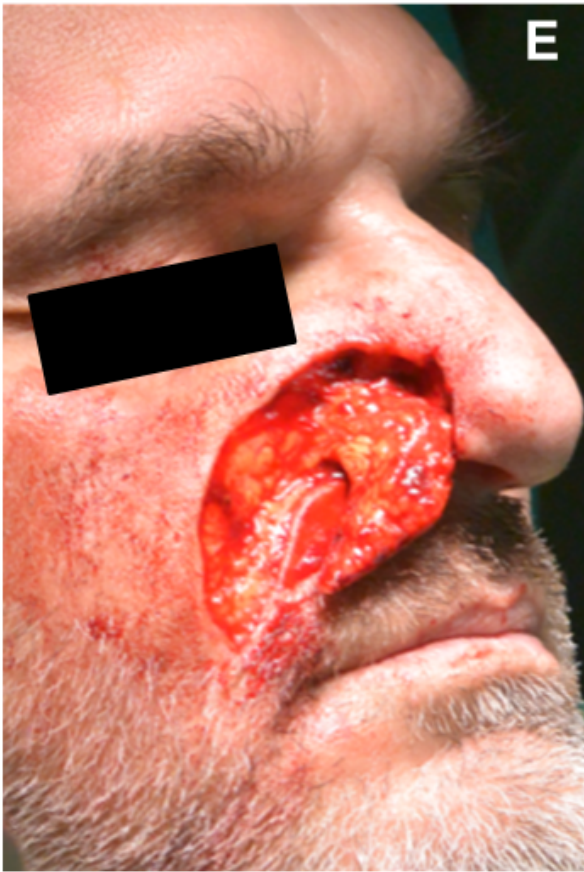
Figure 3. A) Flap elevated including subcutaneous tissue, turned over and thinned; B) cheek wound margin undermined.

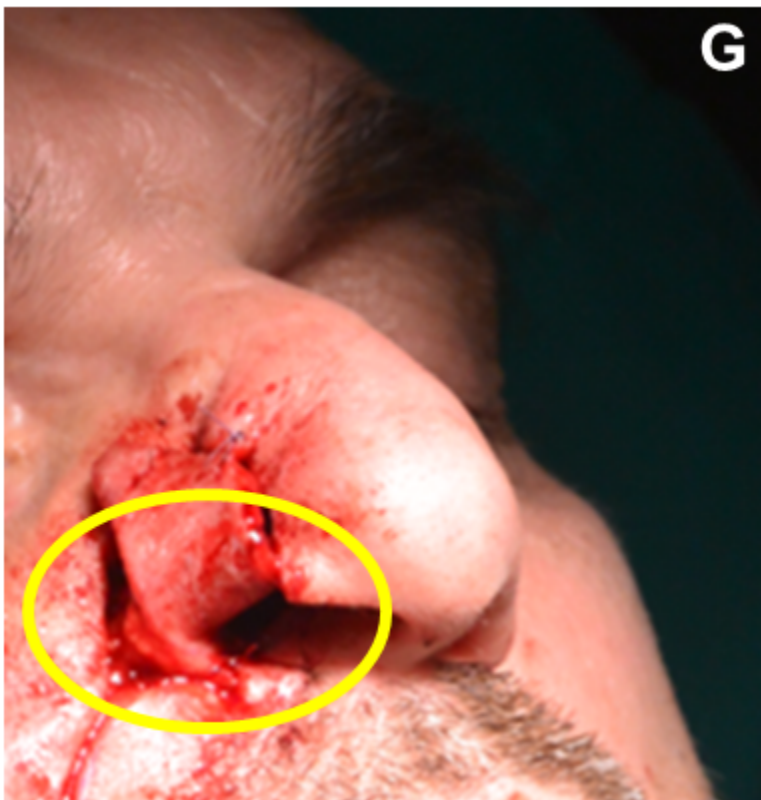

Figure 4. Rotated lateral aspect of the folded flap.

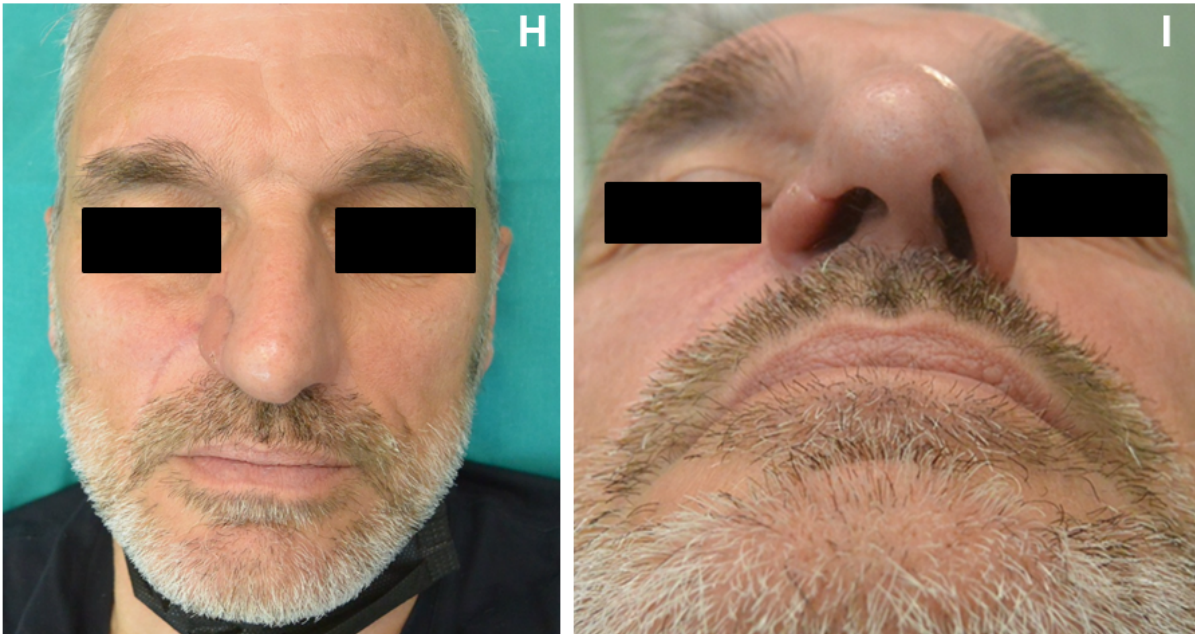

Figure 5. Vertical discrepancy observed.

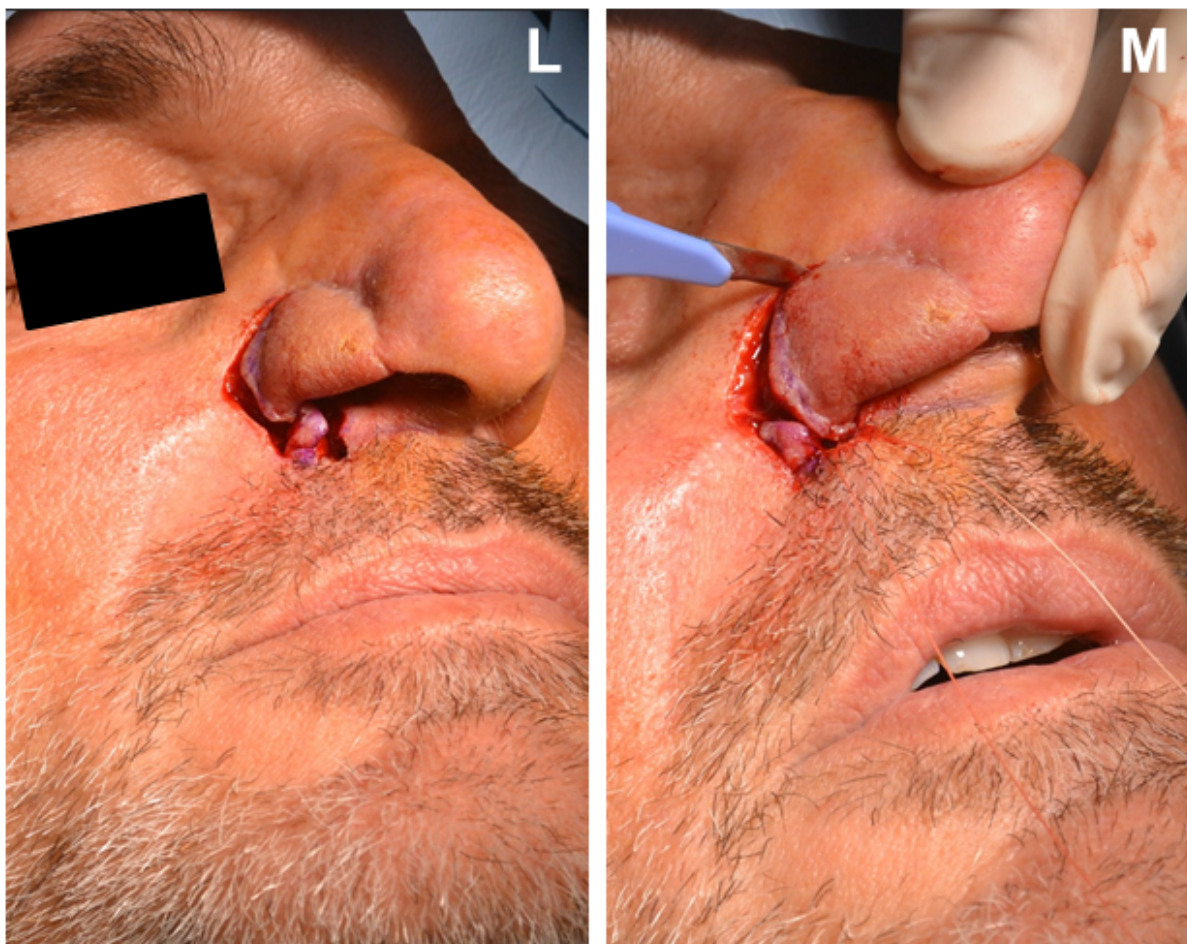


Figure 6. A) Nasal ala rotated caudally; B) alar base medially moved.

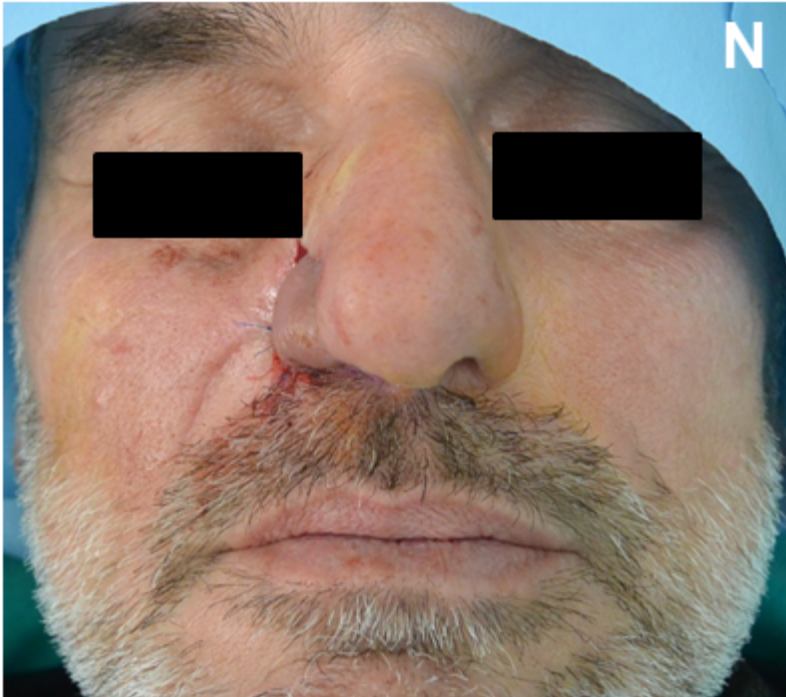

Figure 7. Removed sutures.

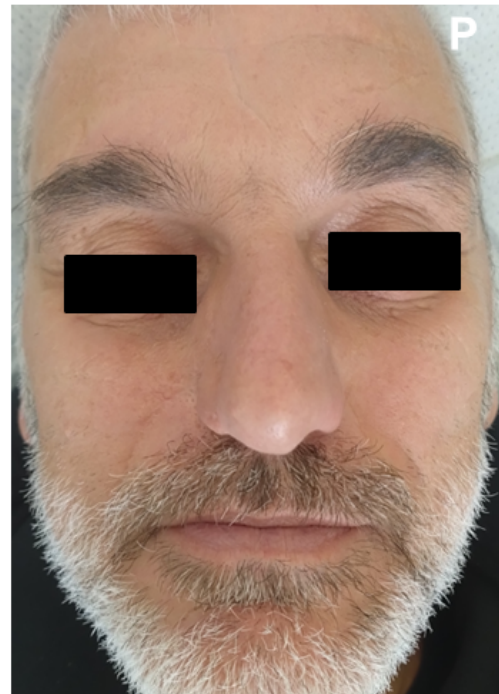
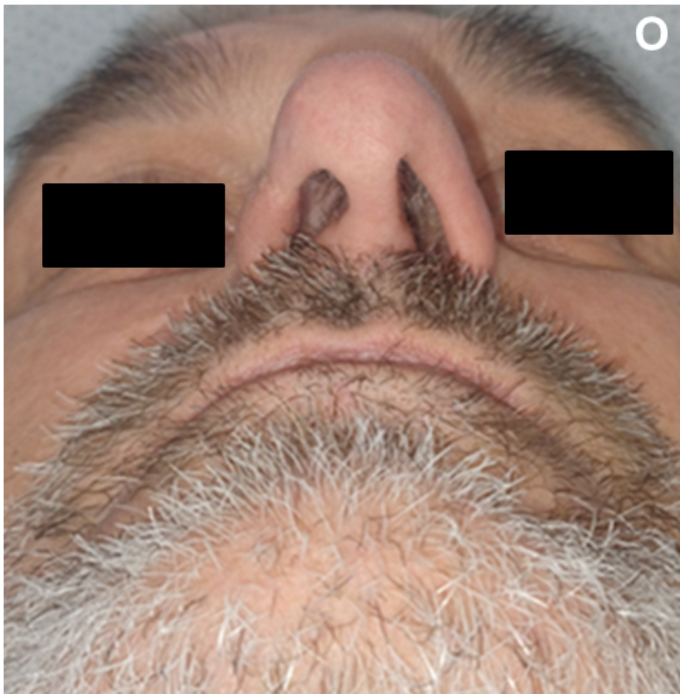
Figure 8. Columella deviation was reduced.