

# Anatomic humeral head replacement with a press-fit prosthesis: An *in vivo* radiographic study

Bryan Vopat,<sup>1</sup> Jeremy Truntzer,<sup>2</sup>  
Daniel Aaron,<sup>3</sup> Jack Anavian,<sup>4</sup>  
Joel Schwartz,<sup>5</sup> Andrew Green<sup>6</sup>

<sup>1</sup>Department of Orthopaedic Surgery,  
University of Kansas, Kansas City, KS;

<sup>2</sup>Department of Orthopaedic Surgery,  
Stanford University, Stanford, CA;

<sup>3</sup>Orthopaedic Surgeon, UMass Memorial  
Health Care, Worcester, MA;

<sup>4</sup>Southern California Permanente  
Medical Group, Fontana, CA;

<sup>5</sup>Department of Orthopaedic Surgery,  
Warren-Alpert School of Medicine at  
Brown University Medical School/Rhode  
Island Hospital, Providence, RI;

<sup>6</sup>Division of Shoulder and Elbow  
Surgery, Department of Orthopaedic  
Surgery, Warren-Alpert School of  
Medicine, Brown University Medical  
School/Rhode Island Hospital,  
Providence, RI, USA

## Abstract

Successful total shoulder arthroplasty is, in part, dependent on anatomic reconstruction of the glenohumeral joint. The purpose of this study was to evaluate the post-operative anatomy of total shoulder arthroplasty with an anatomic implant design in patients with primary glenohumeral osteoarthritis and compare it to published normative anatomic measurements. Fifty-one patients (56 shoulders) with primary glenohumeral osteoarthritis were treated with a press-fit humeral component as part of a total shoulder arthroplasty (Aequalis, Tornier, Edina, Minnesota). Analysis of postoperative true anterior posterior radiographs was performed with use of a custom software algorithm. The mean humeral inclination (head-shaft angle), mean humeral implant anatomical humeral axis, mean greater tuberosity height, and mean humeral head center offset (medial offset) were  $135.4 \pm 5.1^\circ$ ,  $1.73 \pm 1.7^\circ$ ,  $6.9 \pm 2.4$  mm, and  $3.8 \pm 1.8$  mm, respectively. All parameters were within the ranges reported in the literature for normal shoulders except the mean humeral head center offset, which was less than reported in the literature. Anatomic parameters of a total shoulder arthroplasty can be achieved with an anatomically designed, modular adaptable

press-fit design. Reduced medial humeral head center offset was likely dependent upon implant specific design parameters.

## Introduction

Successful total shoulder arthroplasty (TSA) is, in part, dependent on anatomic reconstruction of the glenohumeral joint.<sup>1,2</sup> Humeral prosthetic designs have evolved since Neer's original monoblock (non-modular) design which was available with only one humeral head radius of curvature and two humeral head height sizes. Improvements in design to facilitate anatomic reconstruction have been a major focus of more recently introduced shoulder arthroplasty systems. Implant modifications including humeral head modularity, variable neck-shaft angles, and variable humeral head offset are now standard in most implant designs, and are thought to facilitate anatomic reconstruction of proximal humeral anatomy and glenohumeral relationships.<sup>3,4</sup>

The importance of anatomic reconstruction of the proximal humerus has been highlighted by a number of investigations on the effect of prosthetic proximal humeral anatomy on shoulder biomechanics and kinematics. Nyffeler *et al.* used the Neer II humeral prosthesis in a cadaveric model to demonstrate that increased humeral prosthesis height relative to the greater tuberosity has a significant detrimental effect on the maximum abduction angle, as well as the moment arms of the infraspinatus and subscapularis muscles.<sup>5</sup> Buchler and Farron compared the effects of a Neer II humeral arthroplasty to those of a custom anatomic arthroplasty and found that the anatomic shoulder arthroplasty restored nearly normal glenoid contact positions with significantly less maximum contact pressures.<sup>6</sup> Williams *et al.* used passive and active shoulder range of motion after a TSA in a cadaver to study the effect of humeral head position on glenohumeral translation, range of motion, and subacromial contact.<sup>7</sup> They found that humeral articular malposition of 4 mm or less resulted in only small changes in humeral translations and range of motion. In contrast, malposition of greater than 4 mm resulted in increased subacromial contact and an offset of 8 mm resulted in significant decreases in passive range of motion.<sup>7</sup> These findings support the use of an anatomic humeral implant design for total shoulder arthroplasty.

Glenohumeral osteoarthritis is associated with variable deformity of the humeral head including anatomic neck osteophytes, humeral head flattening and eccentric

Correspondence: Andrew Green, Division of Shoulder and Elbow Surgery, Department of Orthopaedic Surgery, Warren-Alpert School of Medicine, Brown University Medical School/Rhode Island Hospital, 2 Dudley St., Suite 200, Providence, RI 02905, USA.  
Phone: 401-457-1567 - Fax: 401-831-8637.  
E-mail: agshoulder@aol.com

Key words: Glenohumeral arthritis, Shoulder arthroplasty, Humeral head replacement, Press-fit stem, Anatomic reconstruction.

Contributions: BV led study design and writing of manuscript. Provided key insight on the introduction and discussion sections of the manuscript. JT led sub-study on radiographic validation to determine the impact of humeral rotation on image accuracy. Also contributed to editing and submission of manuscript. DA, key contributor to production of manuscript and member of surgical team for many of the included cases. JA involved in validation study. Also contributed to the design of the modeling software. JS, lead programmer on the Matlab software. Worked intimately with entire research team regarding development of software and statistical analysis of findings. AG, principal investigator of project. Primary surgeon on cases included in study. Expert in the field of total shoulder arthroplasty.

Conflict of interest: one of the authors receives royalties and is a paid consultant of Tornier, Inc., is an Honorarium for DJO, Inc. has received financial support from Arthrex, holds stock from IlluminOSS Medical and Pfizer, has received other financial support from Smith and Nephew, holds IP royalties with Wright Medical Technology, is on the editorial or governing board of the Journal of Bone and Joint Surgery the American Shoulder and Elbow Surgeons and Techniques in Shoulder and Elbow Surgery, and holds a board or committee member position with AAOS. One of the authors is on the editorial or governing board of the World Journal of Orthopaedics.

Further information: this study was IRB approved by Lifespan Rhode Island Hospital IRB1.

The IRB title: CMTT/PROJ: 000412

Received for publication: 3 April 2017.

Accepted for publication: 2 July 2017.

This work is licensed under a Creative Commons Attribution NonCommercial 4.0 License (CC BY-NC 4.0).

©Copyright B. Vopat *et al.*, 2017  
Licensee PAGEPress, Italy  
Orthopedic Reviews 2017;9:7168  
doi:10.4081/or.2017.7168

humeral head wear that can hinder anatomic reconstruction of the proximal humerus. A limited number of studies have investigated

the accuracy of anatomic reconstruction of shoulder arthroplasty systems and there are no *in vivo* studies of current generation shoulder arthroplasty systems that have evaluated the ability to reconstruct shoulder anatomy in patients with glenohumeral osteoarthritis.

The purpose of this study was to evaluate the post-operative anatomy of total shoulder arthroplasty with an anatomic humeral implant design in patients with primary glenohumeral osteoarthritis and compare it to published normative anatomic measurements.

## Materials and Methods

This study was approved by the investigational review board of Lifespan/Rhode Island Hospital (Providence, Rhode Island, NY, USA). Fifty-one patients (56 shoulders) with primary glenohumeral osteoarthritis who were treated with a total shoulder arthroplasty that incorporated a press-fit humeral component (Aequalis, Tornier, Edina, MN, USA) were identified from one surgeon's database of total shoulder arthroplasties. There were 19 males and 32 females with a mean age of 68 years (range 39-89). Patients with post-traumatic arthritis, inflammatory arthritis, and full thickness rotator cuff tear were excluded. In addition, subjects were included only if they had acceptable post-operative true anterior posterior plain radiographs, as determined by the senior author.

### Surgical technique

All of the procedures were performed by the senior author (AG), an experienced fellowship trained shoulder specialist. A standard deltopectoral approach was used. The upper one centimeter of the pectoralis major insertion was released. The subscapularis tendon and anterior capsule were elevated directly off of the lesser tuberosity and capsular releases were performed to mobilize the subscapularis muscle tendon unit and achieve appropriate soft tissue balance. Humeral neck osteophytes were removed and the anatomic neck of the humerus was identified and used as a guide for the humeral osteotomy. The articular segment of the humerus was resected using an oscillating saw with the cut made at the level of the anatomic neck of the humerus following the natural version of the individual patient.

The proximal humerus was prepared using the Aequalis (Tornier, Inc., Edina, MN, USA) press-fit instrumentation. The proximal humerus was prepared with com-

paction broaching until either a satisfactory press-fit was achieved or up to the size determined with the axial reamer. Glenoid exposure and preparation were carried out in standard fashion.

The humeral head size was determined with two methods. The resected humeral articular segment was held up to the trial humeral heads to compare the diameter of the cut surface and thickness of the bone. The selected trial head was then placed onto the taper of the humeral implant and the humeral head offset position was selected to provide the best coverage of the proximal humerus. Specific attention was paid to the anterior, lateral and posterior conformity of the trial head to the native bone cut surface.

Depending upon the quality of the metaphyseal bone, cancellous bone graft harvested from the patient's humeral head was packed into the metaphysis of the humerus. This served two purposes; i) to enhance the press-fit of the implant, and ii) to adjust the position of the humeral head offset if the trial was not satisfactorily aligned. The subscapularis was repaired with transosseous non-absorbable sutures in an anatomic position.

### Imaging

Post-operative follow-up evaluations were routinely performed at two weeks, six weeks, three months, six months, one year and annually thereafter. Plain radiographs in true anteroposterior and axillary lateral positions were obtained at all post-operative follow-up visits. The plain radiographs were reviewed to identify subjects with high quality true anterior posterior images. Only patients with an acceptable plain radiographs were included in the analysis.

The analysis of a single radiograph for each TSA was performed using custom software written in MATLAB (The MathWorks, Natick, MA, USA). Visual localization of specific anatomic sites on the images including the proximal humerus, the prosthetic humeral implant, and the glenoid implant was performed in a semi-automated manner. Image analysis techniques were used to reduce the inherent inaccuracies associated with manual point selection. The software program used these sites to calculate anatomic parameters of the total shoulder arthroplasty including humeral head center offset, head-shaft angle, implant-humeral shaft angle, and humeral head to tuberosity height. All images and the resultant anatomic identifications were individually visualized to ensure accuracy (Figure 1). The circle extrapolated from the humeral head implant was also used to determine the position of the edge of the implant relative to the lateral cortex as

described by Youderian *et al.*<sup>8</sup> If the edge of the sphere was inside of the lateral cortex it was reported as a negative value and if it was outside of the lateral cortex it was reported as a positive value. Image magnification was controlled using radio-opaque markers that were applied to the lateral aspect of the shoulder at the time of the radiograph.

To validate the use of acceptable post-operative radiographs an *in vitro* model was tested to determine the impact of humeral rotation on image accuracy. A sample press-fit modular humeral component (Aequalis) was implanted into a cadaver humerus. The implant was then oriented at a 90-degree angle to the fluoroscopy beam. Two fluoroscopy images were taken at 0 degrees of rotation. Images were then obtained at increasing internal rotation (IR) and external rotation (ER) up to 30 degrees in 5-degree increments. Radiographic analysis was performed using the same custom software adapted to a cadaver humerus with prosthesis. Each parameter was evaluated across all degrees of rotation to identify a relationship between rotation and change in anatomic parameter. The linear correlation coefficient ( $r$ ),  $P$  value, and relative degree of change leading to 5 and 20% variations from 0 degrees of rotation for each parameter were reported using the line of best fit. It was found that the beam needs to be within 5.7 degrees of ER and 13.6 degrees of IR to be within a 5% error for tuberosity to humeral head height and within 17.3 degrees of IR for humeral head offset. All included radiographs for the *in vivo* analysis were found to have rotational offset within the range to produce less than 5% error.

## Results

The distribution of humeral stem diameter, humeral stem angle, humeral head sizes, and humeral head offset positions used in the procedures are listed in Tables 1-4. The calculated post-operative anatomic parameters are listed in Table 5. The mean humeral inclination (head-shaft angle) was  $135.4 \pm 5.1^\circ$  (range  $124^\circ$  to  $146^\circ$ ). The mean humeral implant anatomic humeral axis angle was  $1.73 \pm 1.7^\circ$  (range  $-3.5^\circ$  to  $4.8^\circ$ ) in a valgus position. There were 7 cases in which the humeral implant was in a slight varus position. The mean greater tuberosity to head height distance was  $6.9 \pm 2.4$  mm (range 2.8 to 12.3 mm). The mean humeral head center offset (medial offset) was  $3.8 \pm 1.8$  mm (range 0.2 to 7.7 mm). The position of the humeral head circle relative to lateral humeral cortex was  $-0.49 \pm 2.67$  mm (range 4.76 to -10.04 mm). In 31 cases

the extrapolated circle of the humeral head was inside the lateral cortex and in 29 it was outside. Among this cohort of patients there were no cases of post-operative infection, instability or early reoperation. One patient developed symptomatic glenoid loosening and was revised 6 years after the index procedure by removing the glenoid component and exchanging the humeral head component with a custom implant having an

increased head thickness to maintain the humeral offset and rotator cuff tension.

The calculated anatomic parameters were compared to published normative parameters and were found to closely approximate the previously reported normal values (Table 6).<sup>9-14</sup> The mean greater tuberosity to head height distance was  $6.9 \pm 2.4$  mm. This is comparable to the range of means that has been reported in the

literature of 6.7 to 8.0 mm.<sup>11,14</sup> The mean humeral head center offset (medial offset) was  $3.8 \pm 1.8$  mm. This is somewhat less than the reported range of 6 to 7.6 mm.<sup>9,10,12,14</sup> Lastly, the humeral stems were found to be implanted very close to the anatomic humeral shaft axis, and in order to optimize position of the humeral head component, a number stems were intentionally placed in a slight valgus position.

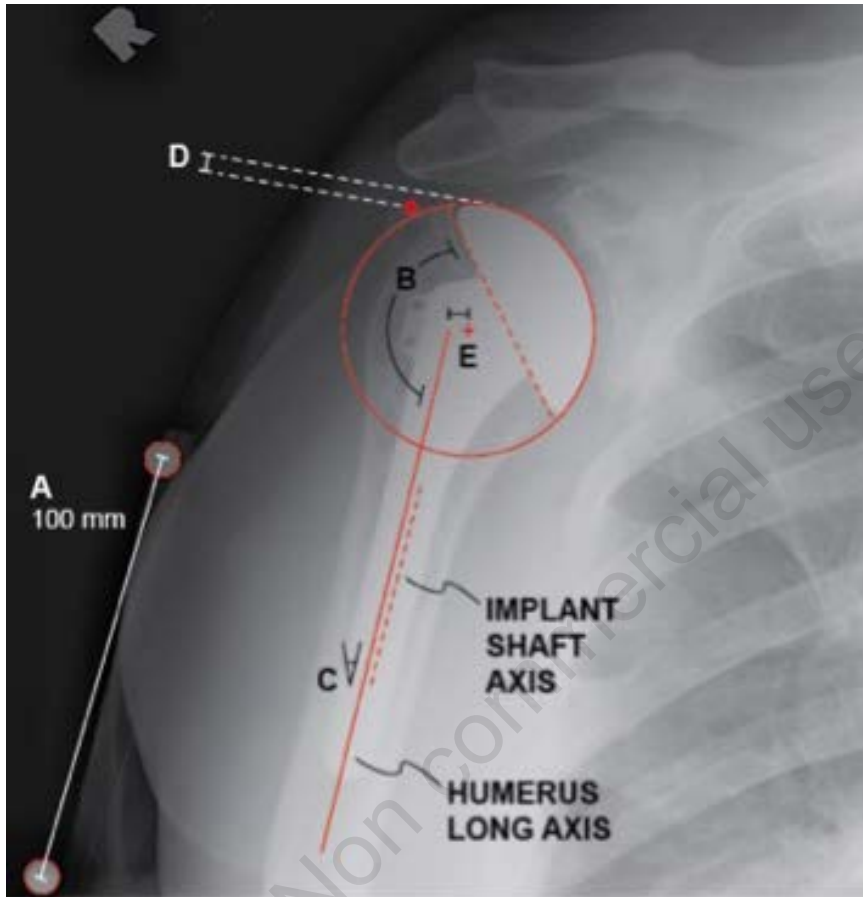


Figure 1. True anterior posterior plain radiograph labeled with anatomic parameters. A standard length radio-opaque marker (A) was used to scale the image. The angle between the humeral shaft axis and the base of the implant head was calculated as the humeral inclination, or head-shaft angle (B). The angle between the implant shaft axis and humeral axis was calculated as the humeral implant anatomical humeral axis (C). The distance between the user-selected point at the tuberosity and a line tangent to the implant articular surface was defined as the greater tuberosity height (D). The minimum distance between the humeral axis and center of the circle fit to the articular surface was calculated as the humeral head center offset (E).

Table 1. Distribution of humeral implant stem diameter sizes.

Stem diameter	Number of cases (%)
7	5 (9)
9	11 (20)
11	25 (44)
13	15 (27)

Table 2. Distribution of humeral stem implant angles.

Implant angle	Number of cases (%)
125°	4 (7)
130°	23 (41)
135°	24 (43)
140°	5 (9)

Table 3. Distribution of humeral head sizes.

Humeral head size	Number of cases (%)
41×13	2 (4)
43×16	9 (16)
46×17	24 (43)
48×18	13 (23)
50×16	3 (5)
50×19	7 (13)
52×19	9 (16)
52×23	2 (4)

Table 4. Distribution of humeral head offset positions.

Humeral head offset position	Number of cases (%)
1	28 (50)
2	3 (5)
7	1 (2)
8	24 (43)

Table 5. Anatomic parameters after pressfit total shoulder arthroplasty.

Humeral inclination	Humeral implant-anatomic humeral axis angle	Greater tuberosity to head height	Humeral head center offset
$135.4^\circ \pm 5.1^\circ$ (124°-146°)	$1.73^\circ \pm 1.7^\circ$ (-3.5°-4.8°)	$6.9 \pm 2.4$ mm (2.8 mm - 12.3 mm)	$3.8 \pm 1.8$ mm (0.2 mm - 7.7 mm)

Values are expressed as mean±standard deviation (range).

## Discussion

The findings of this study confirm that an anatomically designed modular pressfit humeral implant can be used to achieve the goal of anatomic reconstruction of the proximal humerus in patients with primary glenohumeral osteoarthritis. Perhaps most importantly, restoration of the position of the humeral head articular segment was achieved. The greater tuberosity to humeral head height was restored to values within the range of reported normal anatomy while the humeral head center offset was slightly less than normal.<sup>9,11-13</sup> These parameters are thought to contribute to rotator cuff function as well as glenoid implant loading and contact forces, both being factors that are considered important to post-arthroplasty function and survivorship.

Pearl *et al.* used a two-dimensional computer model to analyze the reconstruction of the humeral head that could be achieved with four different press-fit second generation modular systems and found that none of the prosthetic systems yielded an identical replication of the humeral articular segment.<sup>3</sup> In a subsequent study, Pearl *et al.* used a three-dimensional CT analysis of 60 cadaver shoulders to compare the anatomic reconstruction of four systems one of which was the Tornier Aequalis system (Edina, Minnesota), the same as used in this study, which is an anatomically designed system. They found that the anatomic parameters of the Aequalis were significantly better than those of the other systems, with less displacement of the center of rotation and the articulation point of the humeral head as well as better preservation of the surface arc.<sup>15</sup> More recently, Wirth *et al.* performed humeral arthroplasty on cadavers with a third-generation implant design and demonstrated that the proximal humeral anatomy could be accurately reconstructed.<sup>16</sup>

In our study we found that the humeral inclination was at the mid-range of reported

normal values. The humeral stems were implanted very close to anatomic humeral shaft axis. In some cases a slight valgus position was intentionally selected in order to improve the position of the humeral head component. The Morse taper on the implant studied is located medially, which necessitates lateral offset of the humeral head. In some cases the taper was excessively medial and compromised the lateral coverage of the humerus. This can be adjusted by placing bone graft medially in order to slightly tip the stem into valgus. Similarly, graft can be placed anteriorly or posteriorly to fine-tune the humeral head position.

The slightly reduced humeral offset is likely the result of a lower ratio of head thickness to diameter of the specific implant system that was utilized compared to the normal range of humeral head thickness. Although the implant studied was designed using anatomic data obtained from CT scans to derive a consistent head diameter to thickness ratio, the humeral head center offset in this study was several millimeters less than published normal values. The etiology of this difference is unclear but may relate to the specific cohorts of anatomic specimens and patients studied as well as to the surgical technique of the senior author.

Although no study has clearly demonstrated that anatomic reconstruction results in better clinical outcomes or implant longevity, the results of reported cadaver biomechanical studies support the contention that anatomic reconstruction may lead to fewer late problems and complications including rotator cuff tendinopathy and failure, superior humeral migration, and loosening of the glenoid component.<sup>3</sup> The development of new anatomic TSA designs, with variability in parameters such as modularity, humeral head size, humeral head offset, neck-shaft angle, and offset may allow for a more anatomic reconstruction of the proximal humerus and glenohumeral joint than earlier designs.<sup>3,4</sup> In a cadaveric study, Jeong *et al.* demonstrated that both adjustable and fixed-angle neck-shaft

humeral prostheses can adequately result in an anatomic humeral reconstruction.<sup>17</sup> However, they found that the fixed angle device required modifications to surgical technique to meet anatomic parameters, especially in cases with extreme neck-shaft angles. In a prospective study comparing three prosthetic designs, Razmjou *et al.* evaluated the impact of the prosthetic design on functional and radiographic outcomes after TSA.<sup>18</sup> The designs included the Neer II (Smith & Nephew, Memphis, TN, USA), the Bigliani-Flatow (Zimmer, Warsaw, IN, USA), and the Total Evolution Shoulder System (Biomet France SARL, Valence, France) System. They found that all 3 designs were associated with improved pain, function, and patient satisfaction. However, the Neer II system was associated with limited post-operative active external rotation and radiographic evidence of glenoid and humeral loosening. They concluded that an implant that recreates normal anatomy will provide better function and longer longevity.<sup>2</sup>

Proper positioning of the humeral component is necessary to restore normal glenohumeral kinematics and to prevent impingement and rotator cuff pathology and abnormal contact with the glenoid component.<sup>1</sup> Iannotti *et al.* reported that humeral head malpositioning can result from improper stem insertion, inaccurate medial-lateral and/or anterior-posterior humeral offset, and deviation from an anatomic head-shaft angle, all of which can alter the center of rotation of the humeral head.<sup>1</sup> Youderian *et al.* hypothesized that intraoperative sizing errors could be determined by visualizing the trial implants in the coronal plane in postoperative x-rays.<sup>8</sup> They reported that the projected position of the circle of the humeral head implant should intersect the lateral humeral cortex. In our study the mean distance of the circle from the lateral cortex was  $-0.49 \pm 2.67$  mm.

Terrier *et al.* performed a biomechanical analysis using a 3-dimensional numerical musculoskeletal model of the glenohumeral

**Table 6. Reported series of normal anatomic parameters of the proximal humerus.**

Author	Number of specimens	Head radius of Head curvature (frontal) (mm)	Head height (mm)	Head inclination (°)	Humeral offset (mm)	Head surface arc (°)	Tuberosity head height (mm)	Greater tuberosity offset (hinge point offset) (mm)
Iannotti <i>et al.</i> <sup>11</sup>	140 (96 cadaver, 44 MRI)	24±2.1	19±2.4	135±5	-	-	8±3.2	-
Hertel <i>et al.</i> <sup>10</sup>	200 macerated cadaver	24±2.2	17±1.7	137±3.62	6±1.81	145±5.95	-	5.6±2.58 (critical distance)
Robertson <i>et al.</i> <sup>13</sup>	60 paired fresh cadaver	23±2	19±2	131±3	7±2	-	-	7±2
Boileau <i>et al.</i> <sup>9</sup>	65 (26 paired) fresh cadaver	23.1±2.7	15.2±1.6	129.6±2.9	6.9±2.0	-	-	0
Takase <i>et al.</i> <sup>14</sup>	519 AP patient radiographs	28±3.0	-	140.5±4.0	-	-	6.7±2	-
McPherson <i>et al.</i> <sup>12</sup>	93 embalmed	23.1±2.3	-	141±8.6	7.6±3.2	-	-	-

MRI, magnetic resonance imaging.

joint to show that even a small error in positioning of the humeral component can impact functional outcome and life-time of an anatomic TSA.<sup>19</sup> Inferior malpositioning of the head resulted in impingement and limited abduction, while superior malpositioning resulted in increased risk of subluxation. Both inferior and superior malpositioning caused increased stress on the cement mantle of the glenoid.

The findings of our study demonstrate that an accurate reconstruction can be achieved in shoulders with primary glenohumeral osteoarthritis. The development of an adjustable humeral head offset and variable humeral inclination in conjunction with an anatomically designed humeral head enable the surgeon to accurately reconstruct these parameters despite the pathologic anatomy that is encountered. These design advances are especially important in press fit humeral arthroplasty. Balmer *et al.* noted that the position of a stemmed pressfit implant is highly dependent upon the fit of the stem in the humeral intramedullary canal and that there is little that the surgeon can do to alter the position of the humeral head.<sup>20</sup> They correctly recommended that implant designs incorporate features to compensate for this to ensure an anatomic reconstruction.

We recognize that this study has limitations. The analysis was performed using a two dimensional radiographic image while proximal humeral reconstruction is a three dimensional issue. Nevertheless, the three dimensional reconstruction of the position of the humeral head at the time of surgery was assessed visually and by palpating around the entire edge of the humeral head to confirm that optimal coverage of the exposed cut surface of the proximal humerus was achieved. This study also did not compare pre and post-operative anatomic parameters. It is possible that the extent of pre-operative anatomic pathology has an effect upon the surgeon's ability to reconstruct the anatomy. We also did not determine the normal anatomy of the subjects or compare it to the parameters of the reconstruction. Our comparison to published normal values assumes that the findings of these studies are valid and that they are comparable to those of our subjects. In addition, this study did not assess the clinical outcomes of these patients.

## Conclusions

Optimizing the anatomic parameters of a total shoulder arthroplasty is a desirable goal and can be achieved with an anatomically designed, modular adaptable press-fit humeral design. The objective of this study, *i.e.* to establish that anatomic total shoulder can recreate normal parameters, was achieved. Future studies will focus on the analysis of both anatomic parameters of arthroplasty reconstruction and clinical outcomes in order to determine relevant correlations.

## References

- Iannotti JP, Spencer EE, Winter U, et al. Prosthetic positioning in total shoulder arthroplasty. *J Shoulder Elbow Surg* 2005;14(Suppl.1S):111-21.
- Neer CS 2nd, Watson KC, Stanton FJ. Recent experience in total shoulder replacement. *J Bone Joint Surg Am* 1982;64:319-37.
- Pearl ML, Kurutz S. Geometric analysis of commonly used prosthetic systems for proximal humeral replacement. *J Bone Joint Surg Am* 1999;81:660-71.
- Walch G, Boileau P. Prosthetic adaptability: a new concept for shoulder arthroplasty. *J Shoulder Elbow Surg* 1999;8:443-51.
- Nyffeler RW, Sheikh R, Jacob HA, Gerber C. Influence of humeral prosthesis height on biomechanics of glenohumeral abduction. An *in vitro* study. *J Bone Joint Surg Am* 2004;86:575-80.
- Buchler P, Farron A. Benefits of an anatomical reconstruction of the humeral head during shoulder arthroplasty: a finite element analysis. *Clin Biomech* 2004;19:16-23.
- Williams GR Jr., Wong KL, Pepe MD, et al. The effect of articular malposition after total shoulder arthroplasty on glenohumeral translations, range of motion, and subacromial impingement. *J Shoulder Elbow Surg* 2001;10:399-409.
- Youderian AR, Ricchetti ET, Drews M, Iannotti JP. Determination of humeral head size in anatomic shoulder replacement for glenohumeral osteoarthritis. *J Shoulder Elbow Surg* 2014;23:955-63.
- Boileau P, Walch G. The three-dimensional geometry of the proximal humerus. Implications for surgical technique and prosthetic design. *J Bone Joint Surg Brit* 1997;79:857-65.
- Hertel R, Knothe U, Ballmer FT. Geometry of the proximal humerus and implications for prosthetic design. *J Shoulder Elbow Surg* 2002;11:331-8.
- Iannotti JP, Gabriel JP, Schneck SL, et al. The normal glenohumeral relationships. An anatomical study of one hundred and forty shoulders. *J Bone Joint Surg Am* 1992;74:491-500.
- McPherson EJ, Friedman RJ, An YH, et al. Anthropometric study of normal glenohumeral relationships. *J Shoulder Elbow Surg* 1997;6:105-12.
- Robertson DD, Yuan J, Bigliani LU, et al. Three-dimensional analysis of the proximal part of the humerus: relevance to arthroplasty. *J Bone Joint Surg Am* 2000;82:1594-602.
- Takase K, Imakiire A, Burkhead WZ Jr. Radiographic study of the anatomic relationships of the greater tuberosity. *J Shoulder Elbow Surg* 2002;11:557-61.
- Pearl ML, Kurutz S, Robertson DD, Yamaguchi K. Geometric analysis of selected press fit prosthetic systems for proximal humeral replacement. *J Orthop Res* 2002;20:192-7.
- Wirth MA, Ondrla J, Southworth C, et al. Replicating proximal humeral articular geometry with a third-generation implant: a radiographic study in cadaveric shoulders. *J Shoulder Elbow Surg* 2007;16(Suppl.3):111-6.
- Jeong J, Bryan J, Iannotti JP. Effect of a variable prosthetic neck-shaft angle and the surgical technique on replication of normal humeral anatomy. *J Bone Joint Surg Am* 2009;91:1932-41.
- Razmjou H, Holtby R, Christakis M, et al. Impact of prosthetic design on clinical and radiologic outcomes of total shoulder arthroplasty: a prospective study. *J Shoulder Elbow Surg* 2013;22:206-14.
- Terrier A, Ramondetti S, Merlini F, et al. Biomechanical consequences of humeral component malpositioning after anatomical total shoulder arthroplasty. *J Shoulder Elbow Surg* 2010;19:1184-90.
- Ballmer FT, Sidles JA, Lippitt SB, Matsen FA 3rd. Humeral head prosthetic arthroplasty: Surgically relevant geometric considerations. *J Shoulder Elbow Surg* 1993;2:296-304.